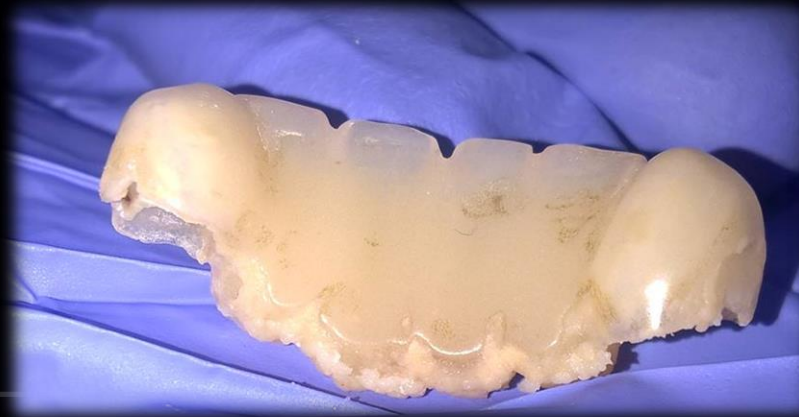
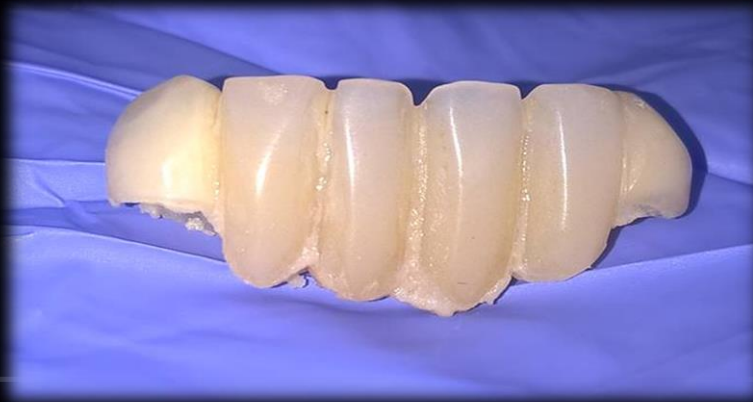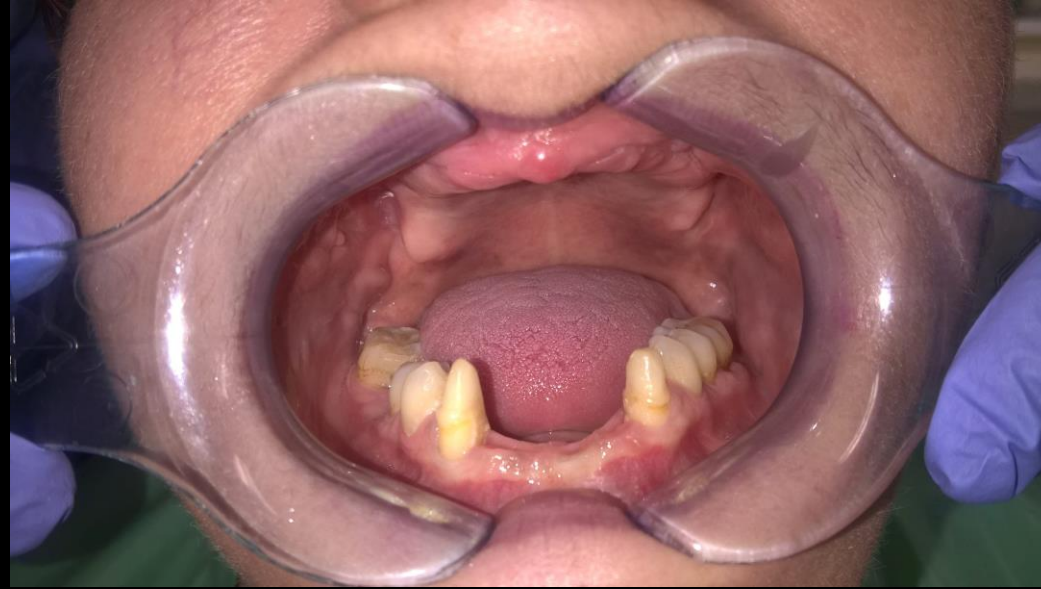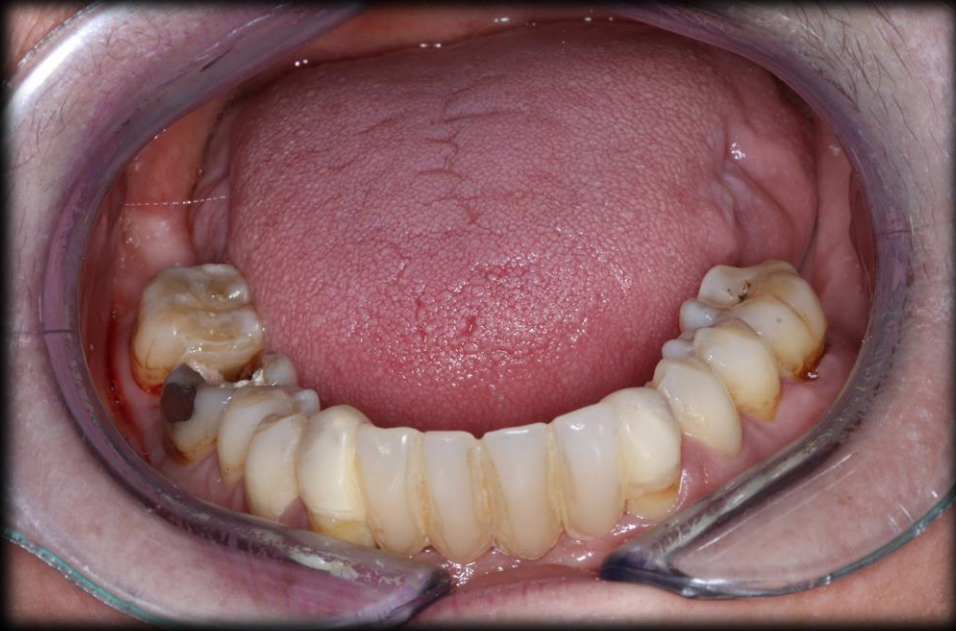


# *CLINICAL PORTFOLIO*

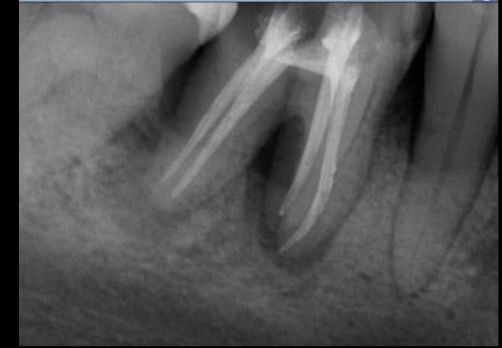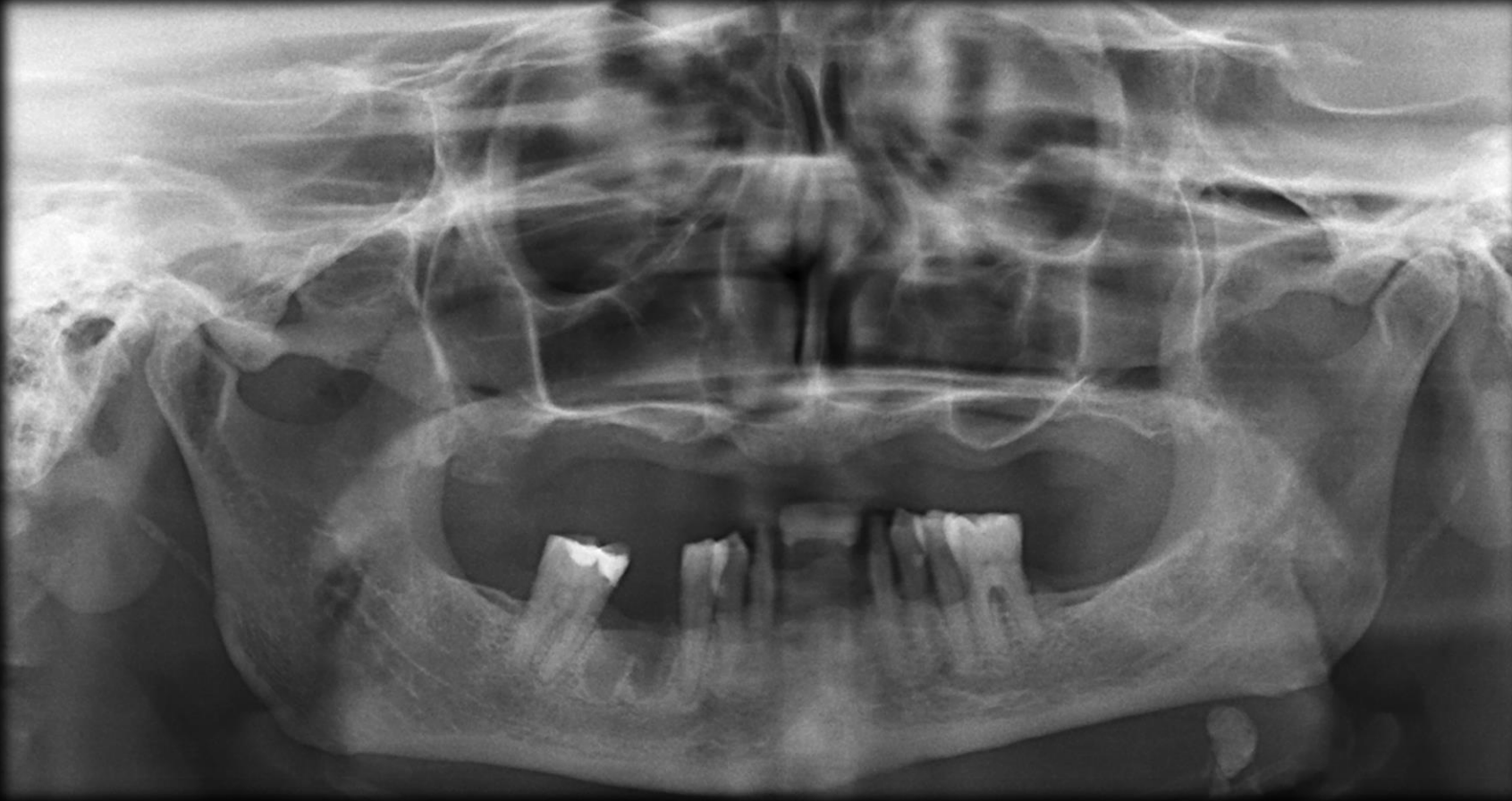
*Tejal Harilal*

# Case 1: Periodontology



- Patient: 48 year old female
- Reason for visit: completion of dental work started by another dentist
- Medical history: back problems, depression
- No allergies
- Medication: Mirapex (Pramipexole)

# Case 1: Periodontology(continued)

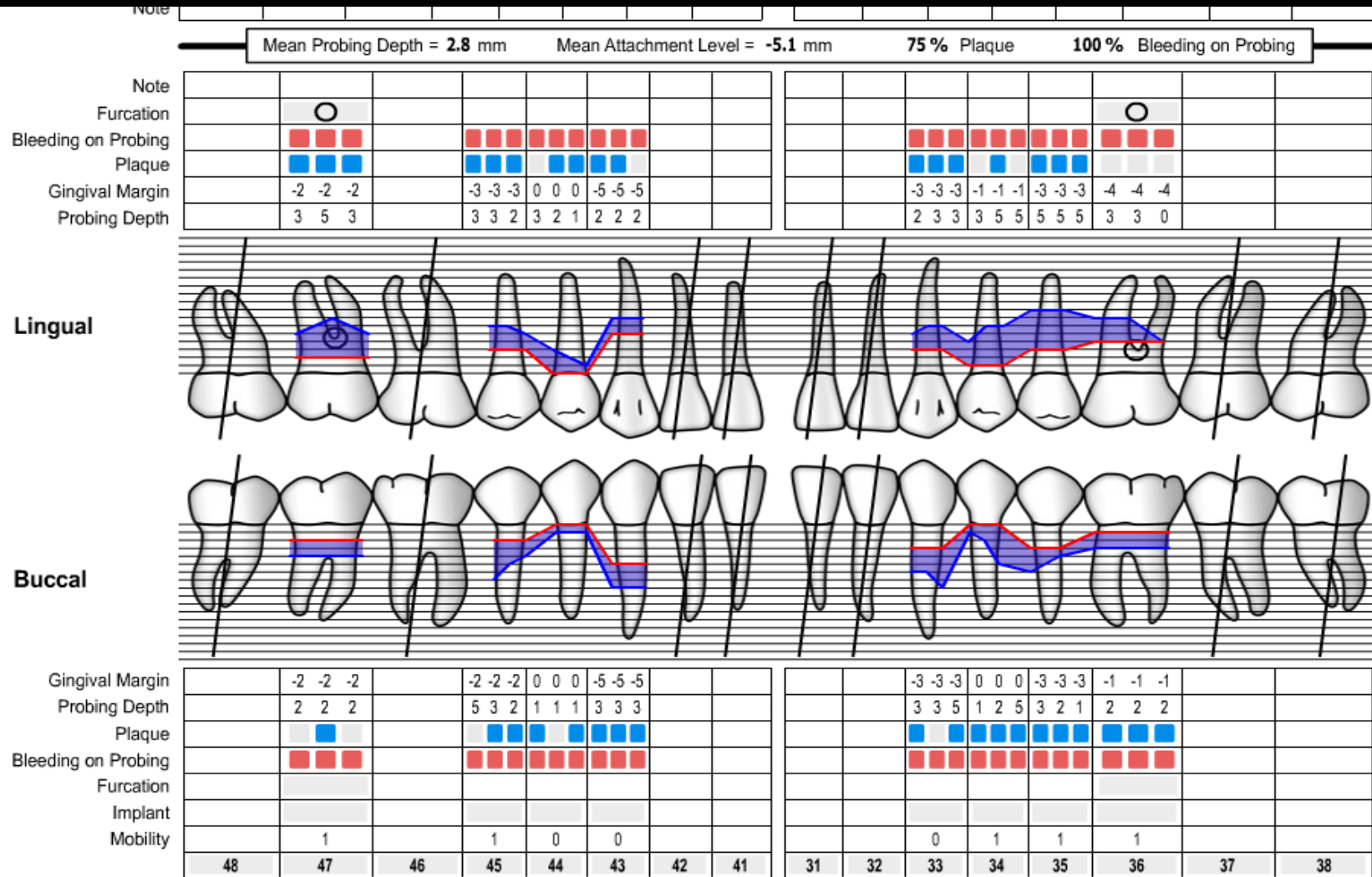


Dg: Chronic generalised periodontitis

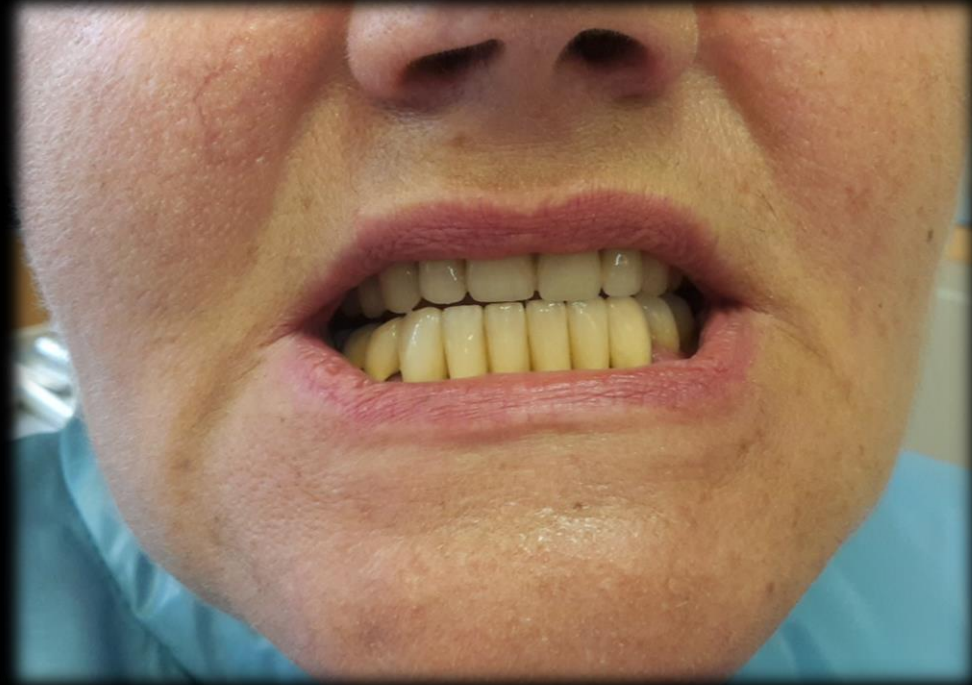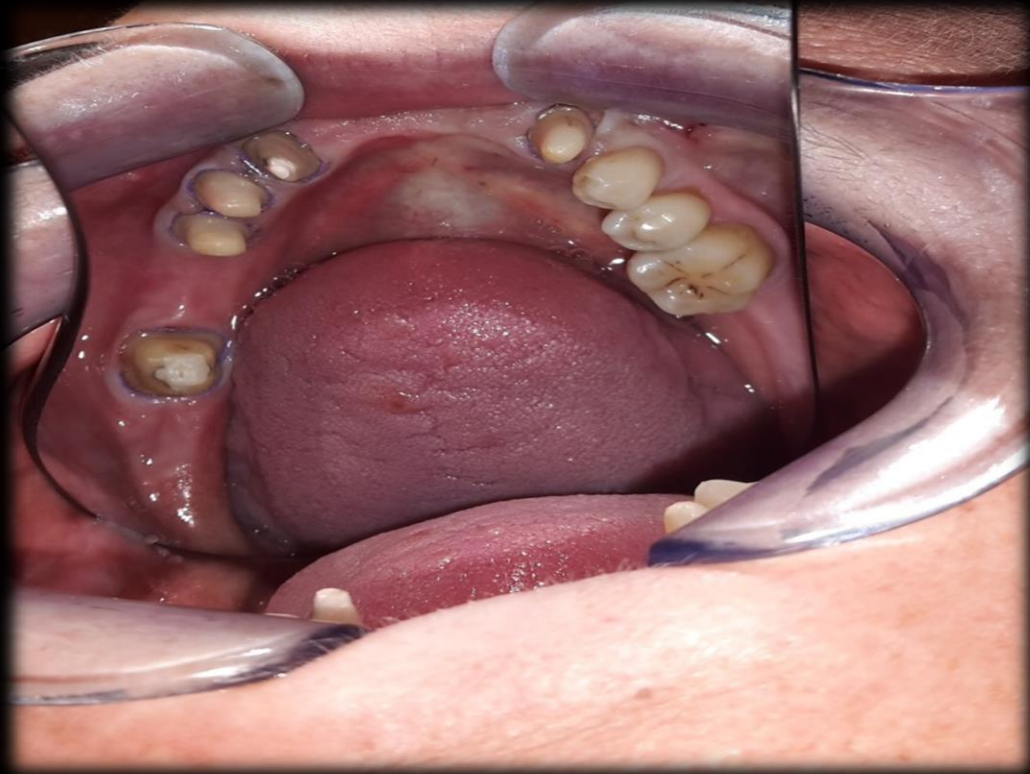
Treatment plan:

- conservative treatment: oral hygiene advice, scale and polish
- 46 extraction
- upper denture relining
- fixed restoration for lower anterior

# Case 1: Periodontology (continued)



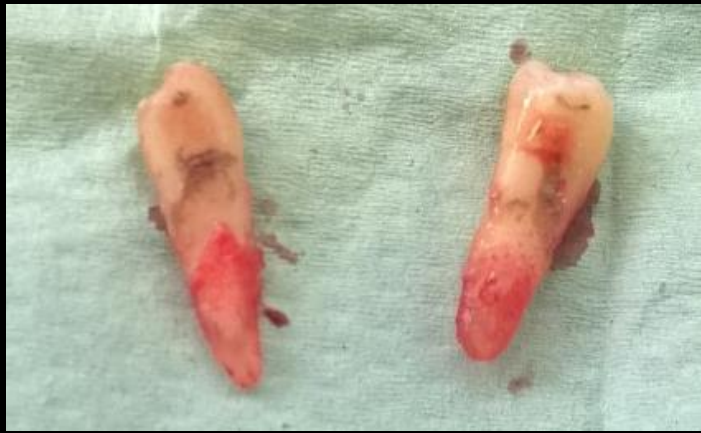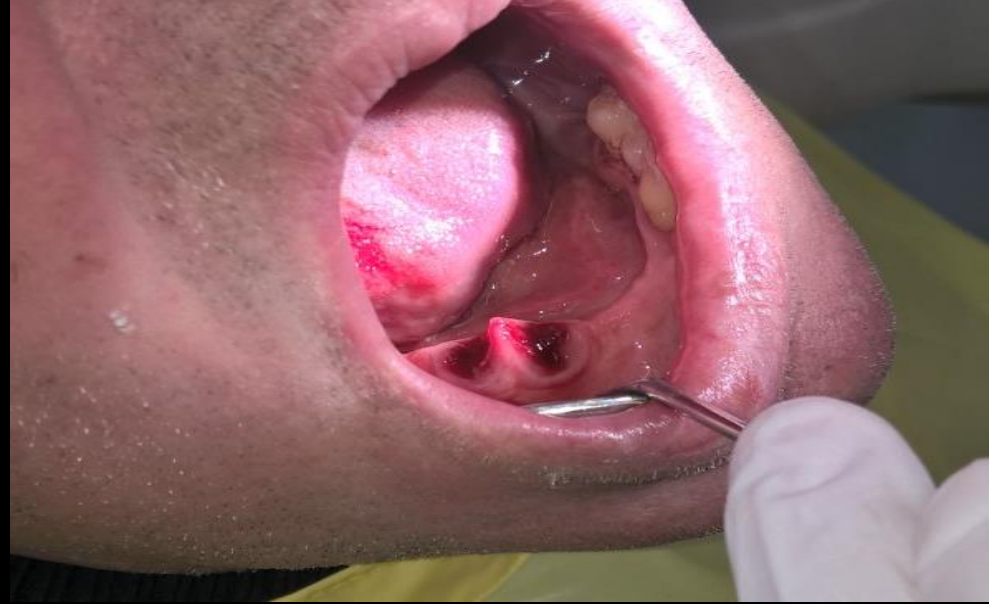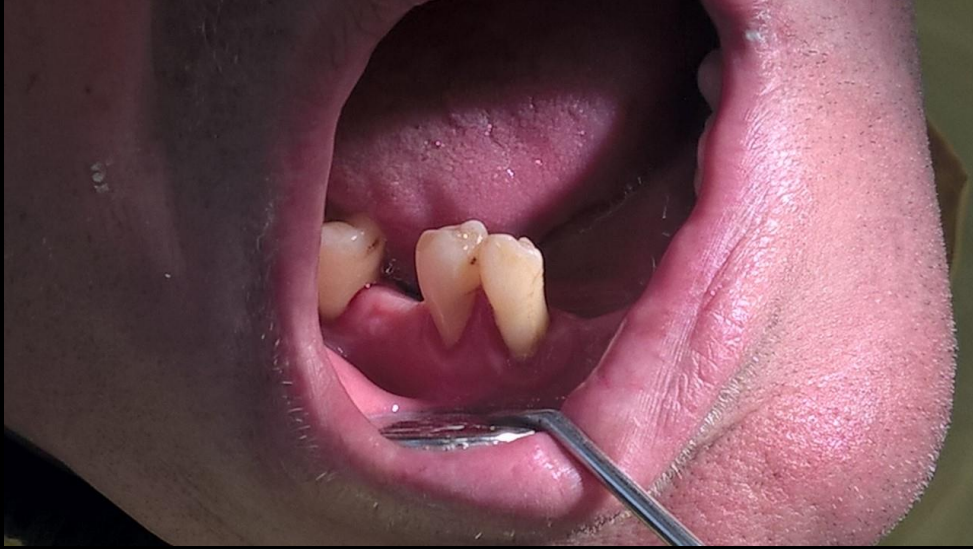# Case 1: Periodontology(continued)



Treatment: perio referral, 46 extraction

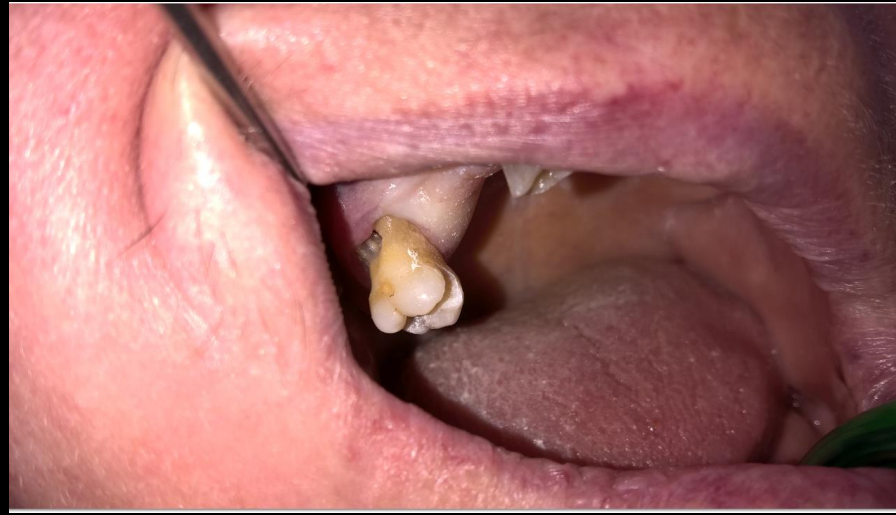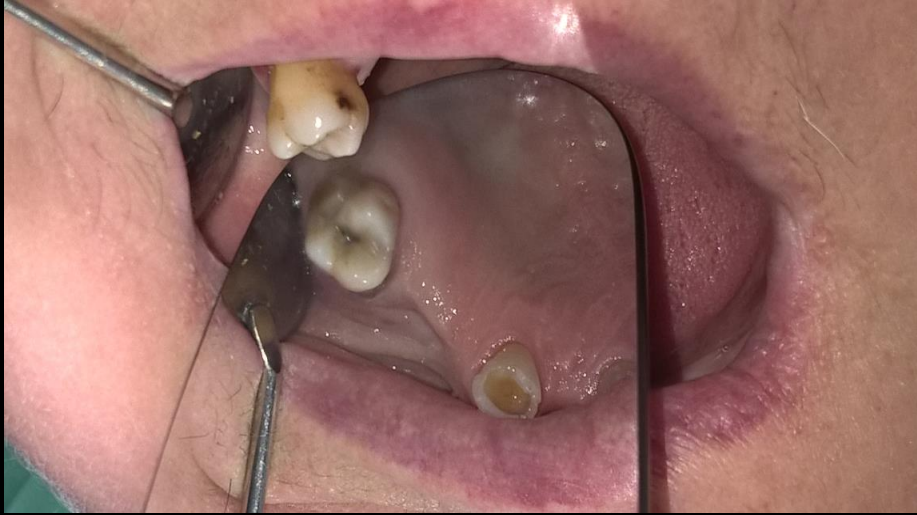- 43 RCT due to extreme sensitivity and pulpitis.
- 33, 43 chamfer line and preparation correction
- Tooth preparation of 44, 45, 47
- 47 RCT

# Case 2: Periodontology



- Patient: 42 year old patient
- Main complaint: cannot bite and eat properly due to mobile teeth. Could not afford any prosthesis or treatment. Wanted them extracted
- History: no diseases, previous extractions due to mobility as well.
- Smoker
- No allergies
- Dg: Grade 3 mobility
- Treatment: oral hygiene advice, 44, 45 extracted.

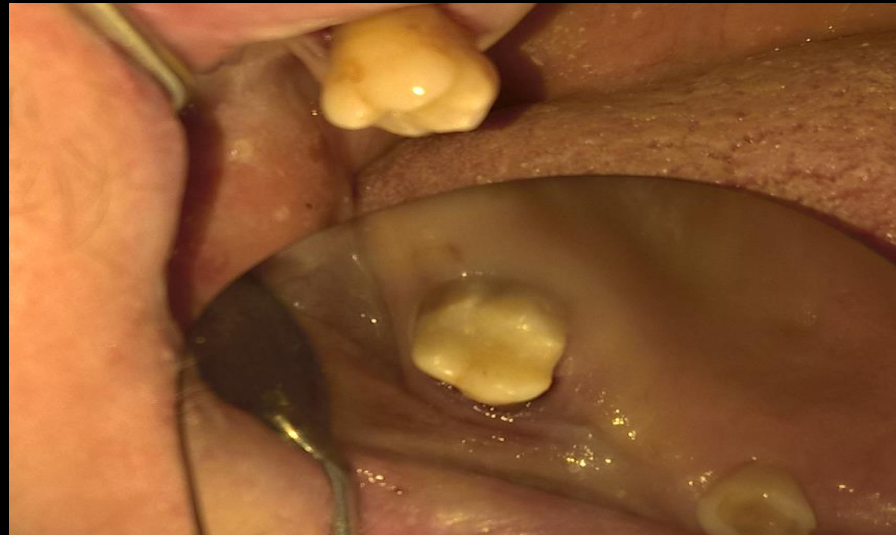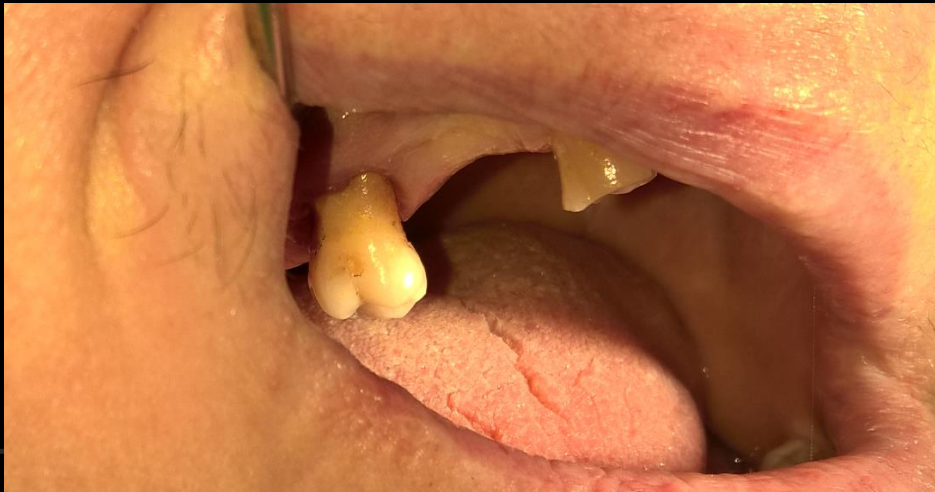# Case 3: restorative



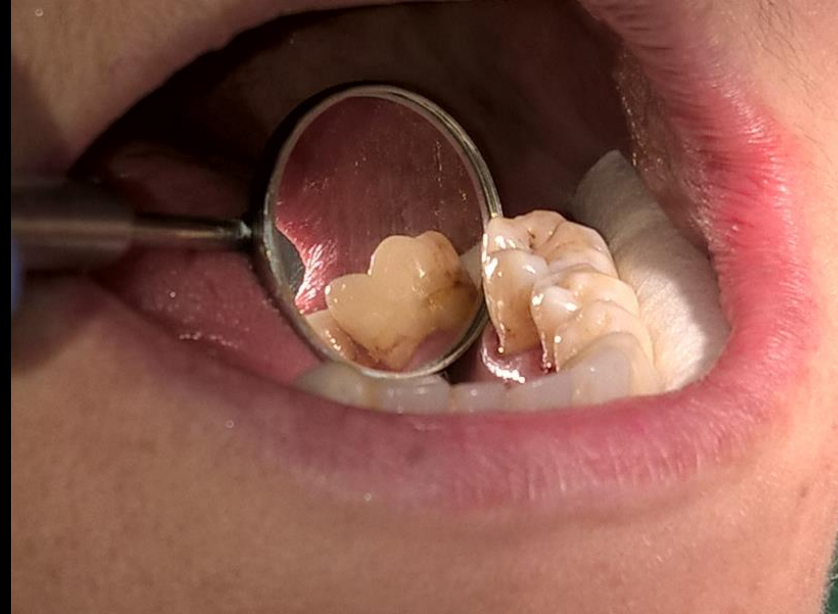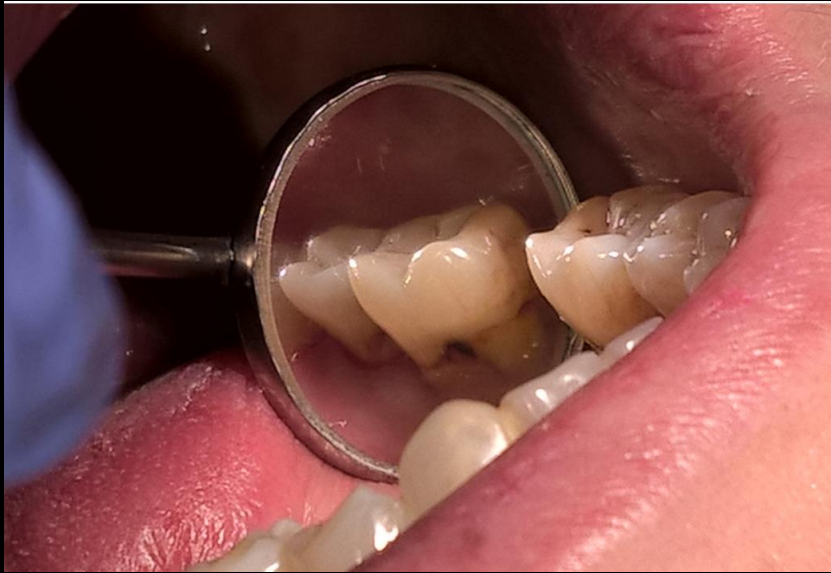Dg: 16 MO  
(caries media)  
and buccal  
cervical caries

Cold vitality test:  
positive

Txt:  
1x2ml local  
lidocaine  
Ionoseal luting  
MO composite  
filling



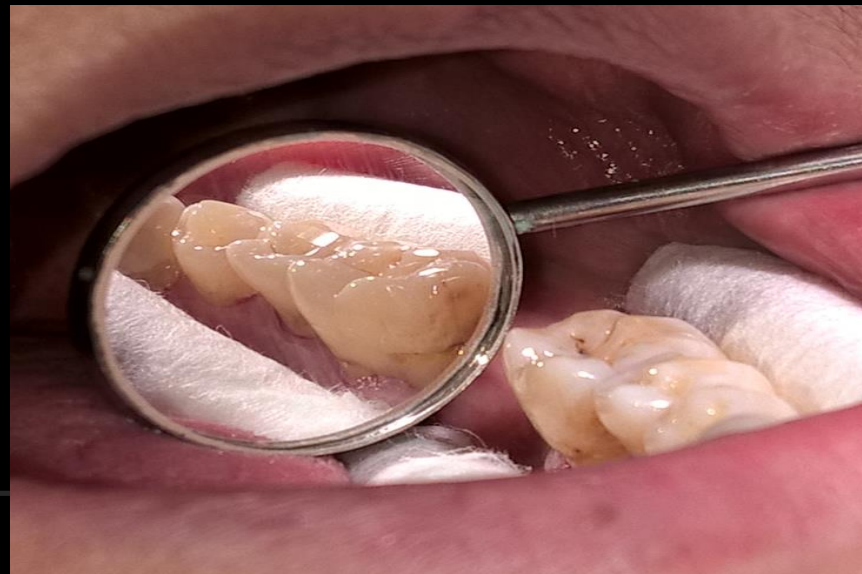# Case 4: restorative



Dg: 36 lingual  
furcation caries

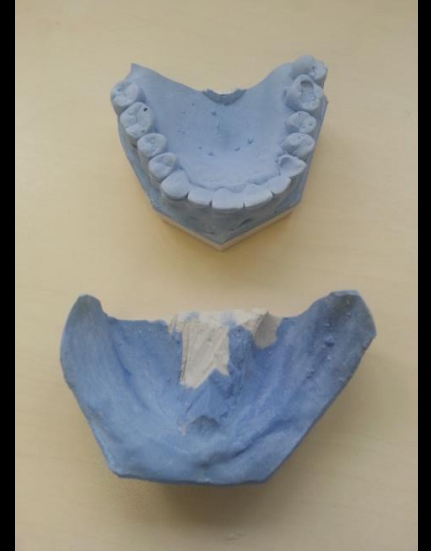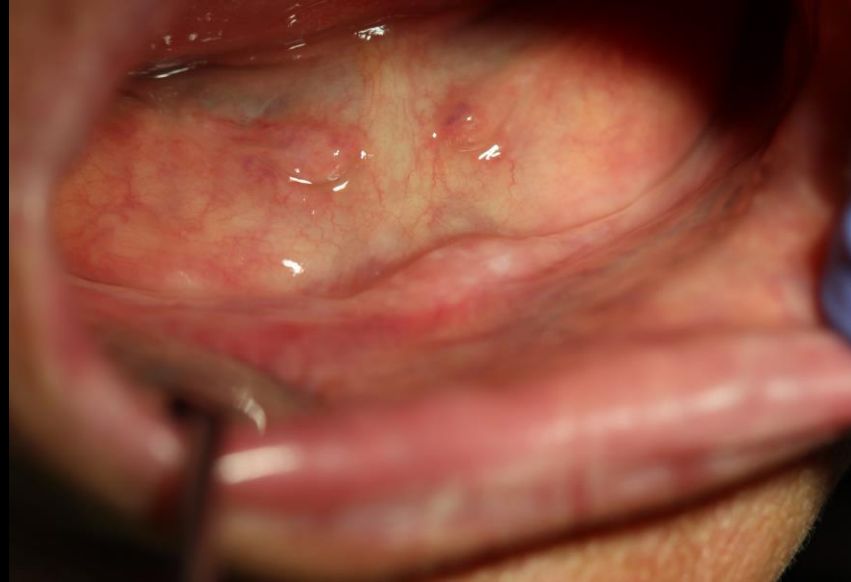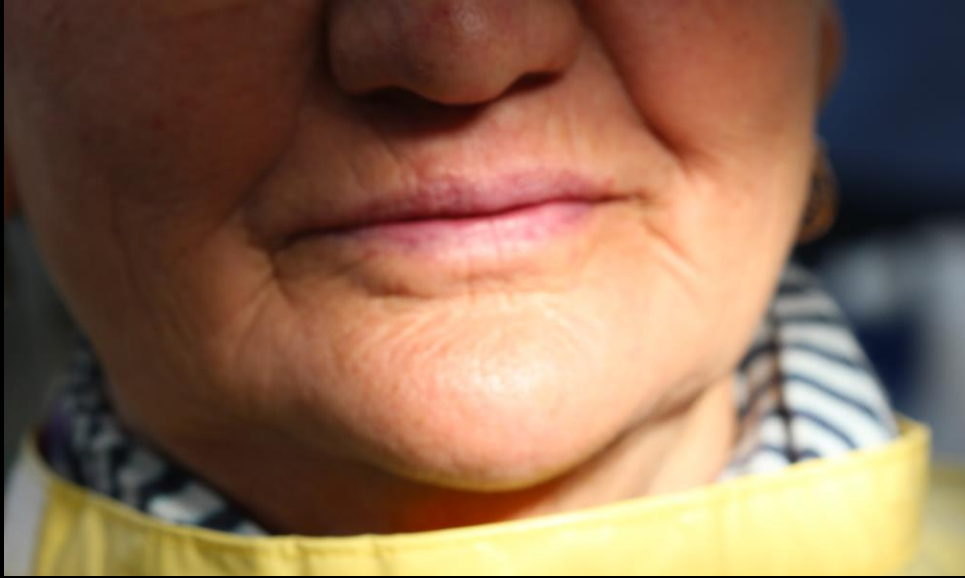Cold vitality test:  
positive

Txt:  
1x2ml local  
lidocaine  
Ionoseal luting  
composite filling

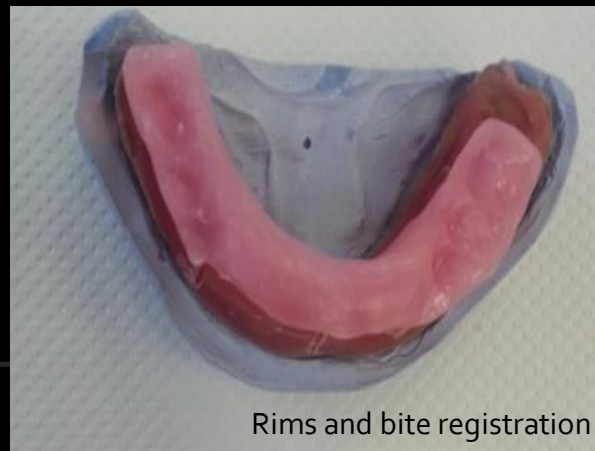



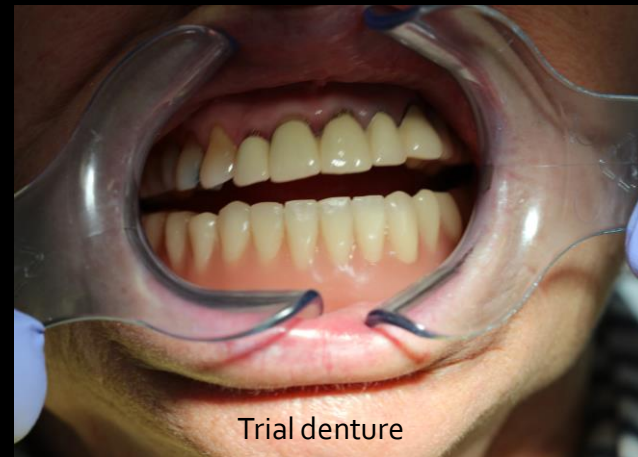
# Case 5: Prosthodontics



Final impression



Rims and bite registration



Trial denture

# Case 5: Prosthodontics (continued)



Patient: 68 year old female

Reason for visit: broken denture

Medical history: gastritis,  
hysterectomy, blood pressure

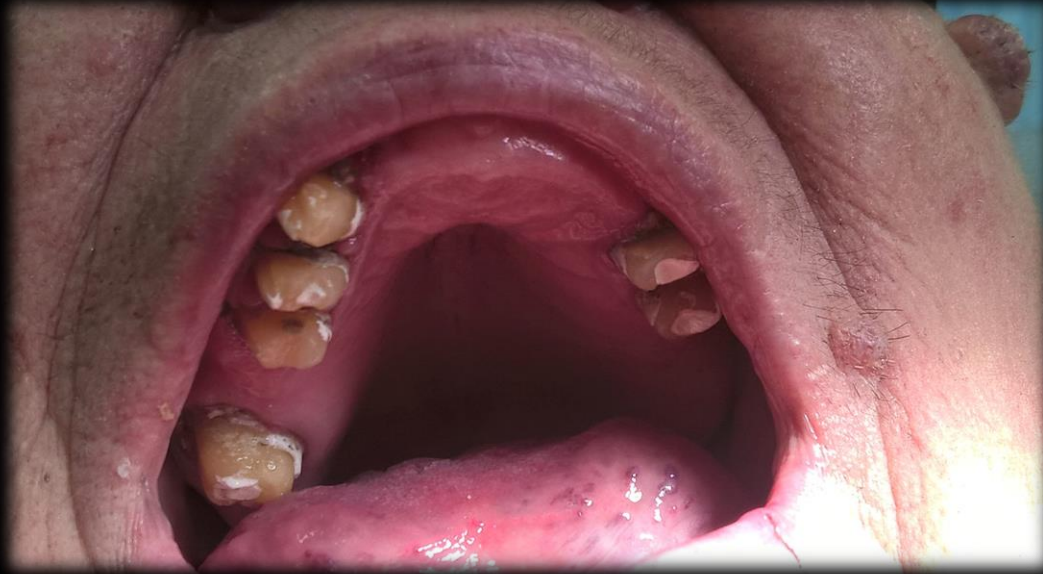No allergies

Medication: ramipil

Dg: anodontia totalis mandibulare

Txt: lower total denture fabrication

# Case 6: Prosthodontics



Patient: 57 year old female  
Reason for visit: metal visible due to wearing away of acrylic from restoration.  
Date of previous restoration: 15 years  
Medical history: constipation, joint aches  
No allergies  
Medication: none

Txt:  
Upper bridge removal,  
sensitivity test for remainder teeth : positive  
fabrication of new bridge (no pictures of final  
result unfortunately)

